


Guillain-Barré Syndrome Triggered by Tetanus Vaccination during Pregnancy: A Rare Case Report

JAGANNATH DHADWAD¹, PRINCE YADAV², KUNAL MODI³, BANA REDDY⁴, CHANDAN KUMAR DASH⁵

ABSTRACT

Guillain-Barré Syndrome (GBS) following tetanus immunisation during pregnancy is an extremely rare occurrence. GBS is an autoimmune disorder in which the immune system targets peripheral nerves, causing muscle weakness and in extreme cases, paralysis. GBS after vaccination, especially after the tetanus, diphtheria and pertussis (Tdap) vaccine, is extremely rare. Here, a case of 21-year-old woman (G2A1, gravida 2, abortion 1) with acute onset of bilateral symmetrical ascending paralysis with areflexia in both upper and lower limbs, with a prior history of Tetanus vaccination 15 days back is described. The patient was examined thoroughly and all other causes were ruled out. Management of this patient was challenging, as it required treating the GBS along with ensuring the wellbeing of the foetus. The aetiological diagnosis also posed a challenge, as there was no clear history of any incriminating cause. Intravenous Immunoglobulins (IVIG) and physiotherapy were given which led to an improvement in the patient's condition. Although the routine practices followed in pregnancy, like vaccination, is vital, this case highlights the potential complications of the same. Reporting such cases is essential to enhance understanding of vaccine safety and guide future recommendations. The clinical implications enforce the need for early diagnosis and prompt management to ensure favourable outcomes for both the mother and foetus.

Keywords: Antenatal care, Autoimmune disease, Immunisation, Intravenous Immunoglobulins, Physiotherapy

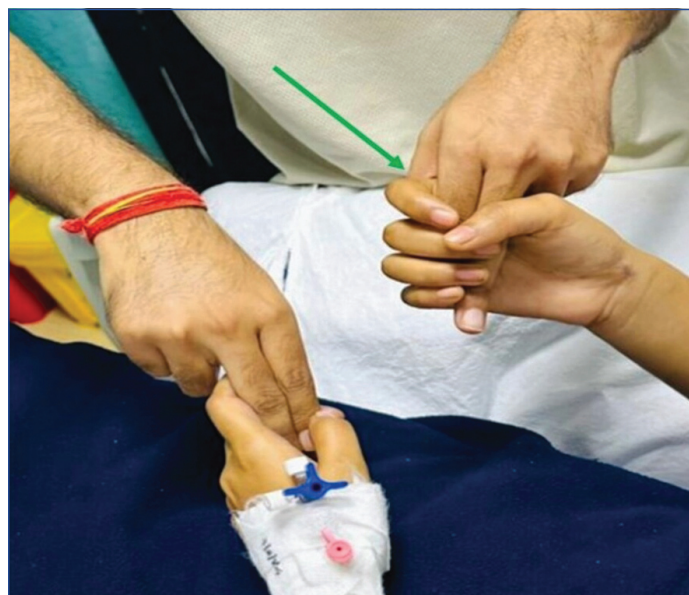CASE REPORT

A 21-year-old female, G2A1, at 16 weeks of gestation, was admitted to the medicine ward with complaints of sudden-onset weakness in her upper limbs, which she first noticed the previous morning upon waking. She found that she could not move her fingers and had difficulty moving both hands. She struggled to hold a spoon and eat, although she had somewhat less difficulty raising her arms to reach for objects on a high cupboard. The following day, she experienced weakness in her legs and feet to the extent that she was unable to walk or stand without support. She also had difficulty transitioning from a supine to a sitting position and moving from side to side, suggesting truncal muscle weakness. Following this, her relatives brought her to the hospital.

She reported no difficulty breathing and there were no signs of slurred speech or facial asymmetry. She denied any history of fever or loose stools prior to the onset of weakness. She was able to feel the clothes on her body and distinguish between hot and cold water, indicative of intact sensation. She did not present with any bowel or bladder dysfunction and she had no visual complaints such as blurred vision or diplopia. There was no significant history or any similar episodes in the past. There was no history of hypertension, diabetes mellitus, bronchial asthma, or any other known comorbidities. The obstetric history revealed an abortion at six weeks of gestation eight months ago. She is currently G2A1 with a single live intrauterine gestation at 16 weeks of maturity. Her vaccination history was notable for receiving a tetanus toxoid vaccination 15 days prior to the presentation of symptoms.

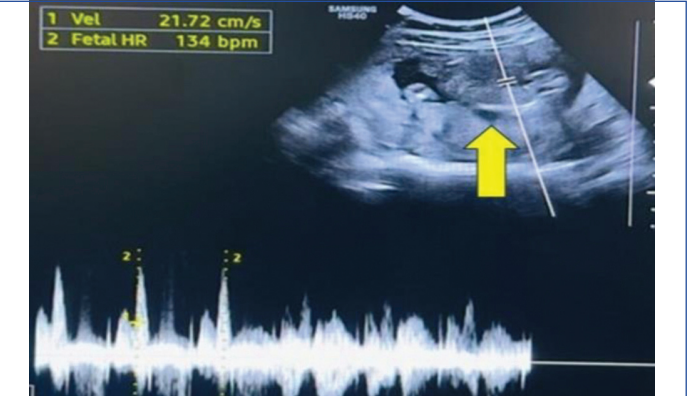During the general examination, her blood pressure was recorded as 110/70 mmHg, with the measurement taken in the right arm while she was lying down. The pulse rate noted was 94 beats per minute with a normal volume and there was no radio-radial or radio-femoral delay in the pulses. All peripheral pulses were palpable. The body temperature measured was 97.4°F and the oxygen saturation (SpO₂) level was 96% on air, with a respiratory rate of 22 breaths per minute. There were no signs of pallor, icterus, cyanosis, clubbing, oedema, or palpable superficial lymph nodes.

Upon systemic examination, the cardiovascular, abdominal and respiratory systems were healthy. The abdominal area was non tender, gravid and spongy. It was discovered that there was areflexia with intact sensation during the central nervous system examination. Bilaterally, there were reactive pupils and no facial weakness observed in the patient, who was conscious and oriented to time, place and person. The extraocular muscles were free and had full range of motion in all directions. The motor examination indicated flaccid tone in both the upper and lower limbs, accompanied by reduced power [Table/Fig-1]. There were no signs of dysphagia or bulbar symptoms and neck flexor strength was preserved. However, truncal weakness was noted. Based on above findings, differential diagnoses considered were infective causes like Human Immunodeficiency Virus (HIV), electrolyte abnormalities, cord compression, transverse myelitis and demyelinating disorders, of which GBS was the most likely.



[Table/Fig-1]: Showing reduced hand grip (green arrow).

An obstetric ultrasound scan [Table/Fig-2] revealed a single intrauterine gestation and a foetal heart rate of 146 beats per minute. Normal foetal movements, adequate amniotic fluid and no foetal abnormalities were observed during the scan. The parameters of foetal growth were within the normal range, as illustrated in [Table/Fig-3].

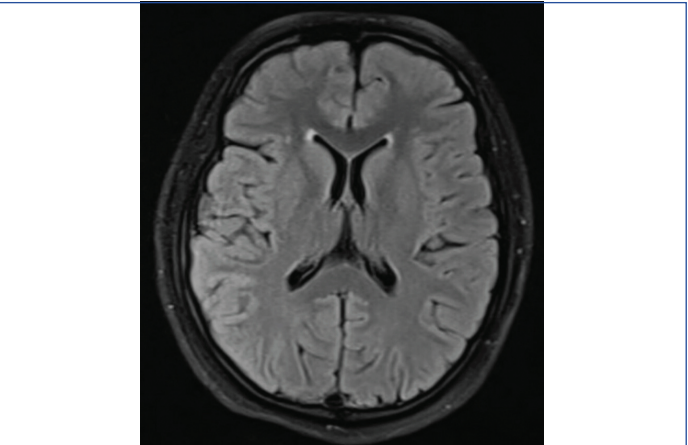


[Table/Fig-2]: Ultrasonography (yellow arrow) showing a live viable foetus of 16 weeks of gestation.

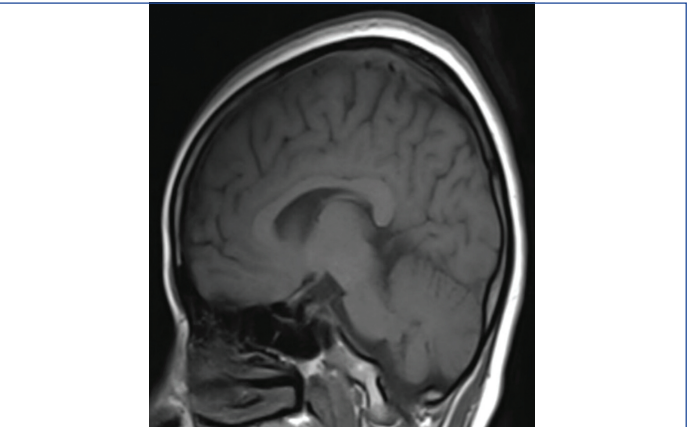
Parameters	Measurement (mm)	Weeks
Biparietal Diameter (BPD)	31	15 weeks and 6 days
Head Circumference (HC)	119	15 weeks and 6 days
Abdominal Circumference (AC)	104	16 weeks and 2 days
Femur Length (FL)	21	16 weeks and 2 days

[Table/Fig-3]: Showing growth parameters.

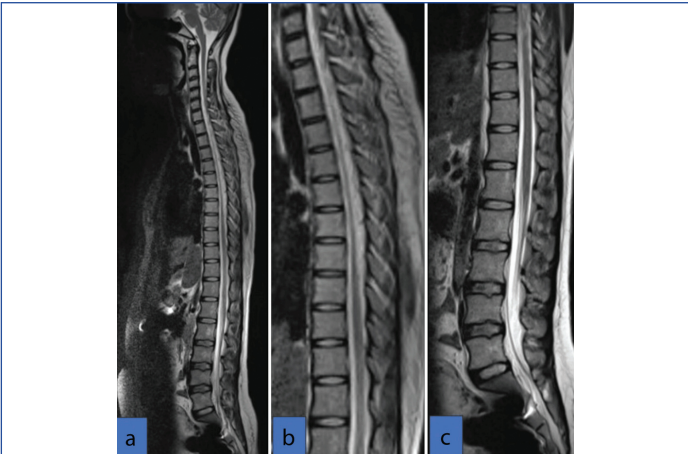
The patient underwent Magnetic Resonance Imaging (MRI) imaging of the brain and spine, which revealed no abnormalities (as shown in [Table/Fig-4-6]). Based on above findings, a provisional diagnosis of GBS was considered. Routine blood samples were sent and no significant abnormality was seen [Table/Fig-7] [1]. The patient was planned for lumbar puncture.



[Table/Fig-4]: MRI brain plain showing no obvious abnormality.



[Table/Fig-5]: MRI brain plain showing no obvious anomaly.



[Table/Fig-6]: MRI SPINE (a-c) reveals no obvious abnormality. a) MRI whole spine screening; b) MRI of dedicated thoracic spine; c) MRI of dedicated lumbar spine.

Investigations	Value	Reference range
Haemoglobin (g/dL)	9.5	11.5-15.0
Total leukocyte count (/ μ L)	9,100	4000-10,000
Platelet count (/ μ L)	3,13,000	150000-410000
Mean corpuscular volume (fL)	76	78-98
Serum bilirubin (mg/dL)	0.21	0.2-1.20
Conjugated bilirubin (mg/dL)	0.11	Upto 0.5
Unconjugated bilirubin (mg/dL)	0.10	0.1-1.0
AST (U/L)	22	8-48
ALT (U/L)	23	7-55
Alkaline phosphatase (U/L)	65	40-130
Total protein (g/dL)	7.10	6.4-8.3
Serum albumin (g/dL)	3.9	3.5-5.2
Serum magnesium (mg/dL)	1.9	1.8-2.40
Serum phosphorus (mg/dL)	4.20	2.6-4.7
Serum sodium (mmol/L)	136.0	136-145
Serum potassium (mmol/L)	3.80	3.50-5.10
Serum chloride (mmol/L)	106	98-107
Urea (mg/dL)	19	17-49
Serum creatinine (mg/dL)	0.57	0.6-1.35
Serum calcium (mg/dL)	9.30	8.60-10.2
Prothrombin time (seconds)	13.20	10.24-12.71
INR	1.11	0.85-1.15
Vitamin D (ng/mL)	17.20	20-50
Total cholesterol (mg/dL)	189	<200
Triglycerides (mg/dL)	58	<150
HDL cholesterol (mg/dL)	55	>40
LDL cholesterol (mg/dL)	118	<100
Serum vitamin B12 (pg/mL)	240	180-890
HbA1c (%)	5.4	4-5.6%
CRP (mg/L)	15.0	>10.0
T3 (ng/mL)	1.49	0.64-1.52
T4 (μ g/mL)	12.49	-11.7
TSH (microIU/mL)	1.71	0.1-2.5
Urine routine	Protein-absent RBCs-absent Acetone-absent Glucose-absent	Protein-absent RBCs- 0-2 per hpf Acetone-absent Glucose-absent

[Table/Fig-7]: Laboratory investigations with reference range [1].
AST: Aspartate aminotransferase; ALT: Alanine transaminase; INR: International normalised ratio; HDL: High density lipoprotein; LDL: Low density lipoprotein; HbA1c: Glycated haemoglobin; CRP: C reactive protein; T3: Triiodothyronine; T4: Tetraiodothyronine; TSH: Thyroid stimulating hormone; hpf: High power field; U/L: Units per litre; mg/dL: Milligrams per decilitre; g/dL: Grams per decilitre; pg/mL: Picograms per millilitre; ng/mL: Nanograms per milliliter; micro IU/mL: Microinternational unit per milliliter

Other laboratory investigations were also sent which did not showed any abnormality [Table/Fig-8]. All special laboratory tests, such as serological tests for *Campylobacter jejuni*, *Mycoplasma pneumoniae*, Epstein-Barr virus, Varicella zoster virus, *Haemophilus influenzae* and Cytomegalovirus, gave negative results.

Investigations	Value	Reference range
ANA blot	Negative	Negative
Uric acid (mg/dL)	2.90	2.70-6.10
Creatinine phosphokinase (U/L)	143.0	26-192
Hepatitis B and C	Non reactive	Non reactive
HIV	Non reactive	Non reactive

[Table/Fig-8]: Special serological labs.

HIV: Human immunodeficiency virus; ANA: Antinuclear antibody; mg/dL: Milligrams per decilitre; U/L: Units per litre

The diagnosis of tetanus toxin-induced GBS was further supported by the results of a lumbar puncture, which revealed albumin-cytological dissociation, as detailed in [Table/Fig-9] (CSF examination). The patient's clinical presentation, laboratory results and absence of any growth in cerebrospinal fluid culture and Cartridge-based Nucleic Acid Amplification Test (CBNAAT) ruled out the other causes of increased Adenosine Deaminase (ADA), thereby supporting to the diagnosis of tetanus toxin-induced GBS.

Investigations	Value	Reference range
Appearance	Clear, transparent	-
Cobweb/Coagulum	Absent	Absent
Deposits	Absent	Absent
Proteins (mg/dL)	47.30	15-45
Glucose (mg/dL)	63	40-80
RBC's	Absent	Absent
Total leukocyte count (/cumm)	2	0-5
Polymorphs	0	-
Lymphocytes	100%	-
ADA (U/L)	15.70	0-5

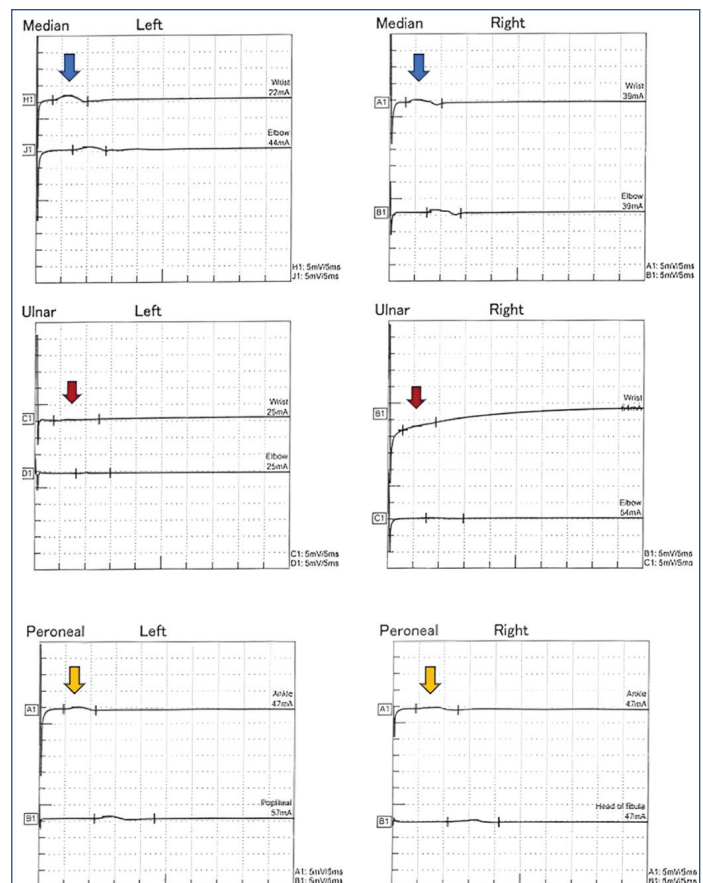
[Table/Fig-9]: Cerebrospinal fluid examination.

RBCs: Red blood cells; ADA: Adenosine deaminase; mg/dL: milligram per decilitre; U/L: Units per litre; cu/mm: Cubic millimeter

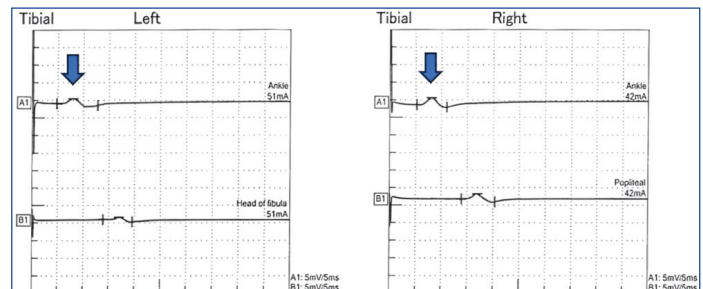
The patient was initiated on IVIG at a daily dose of 0.4 g/kg, in addition to prophylactic low molecular weight heparin, administered subcutaneously at a dose of 0.6 cc. The following day, nerve conduction study confirmed the diagnosis of GBS, specifically the Acute Motor Axonal Neuropathy (AMAN) variant [Table/Fig-10a,b, 11a,b, 12a,b]. The nerve conduction study analysis showed decreased Compound Muscle Action Potential (CAMP) amplitude in right and left median, ulnar, peroneal and tibial nerves, with normal Sensory Nerve Action Potentials (SNAP) and absent F waves in the bilateral median, bilateral ulnar, left peroneal and persistent in left tibial and right peroneal nerves, which were suggestive of AMAN variant in all four limbs.

Above electromyography report showed AMAN involving all four limbs. IVIGs were administered for five days, with careful monitoring of respiratory effort, single breath count, SpO₂, heart rate and foetal heart rate. Post-treatment investigations were conducted, which showed no abnormalities. These investigations yielded normal results, which are detailed in [Table/Fig-13].

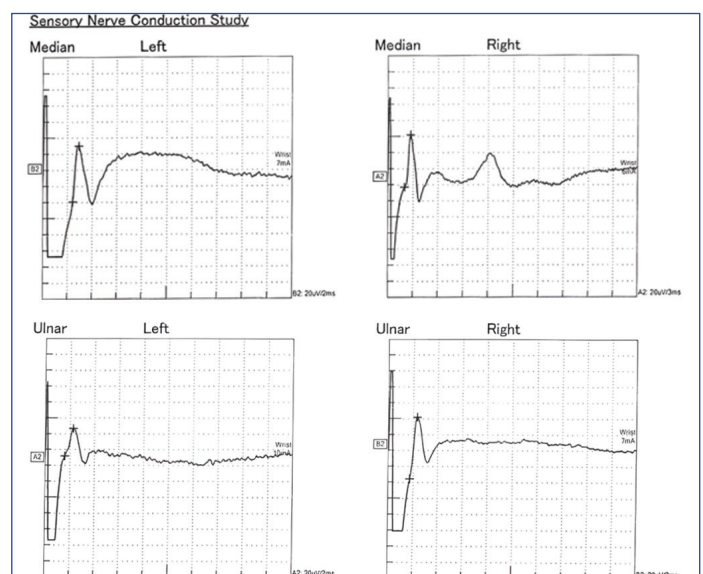
Following IVIGs and physiotherapy, the patient's muscle strength gradually improved. After three weeks of the treatment course she was discharged upon request, with advice to continue physiotherapy at home. The improvement in the patient's strength is summarised in [Table/Fig-14]. After completing the IVIG course and physiotherapy, an improvement in muscle strength in both the upper and lower limbs was observed [Table/Fig-15].



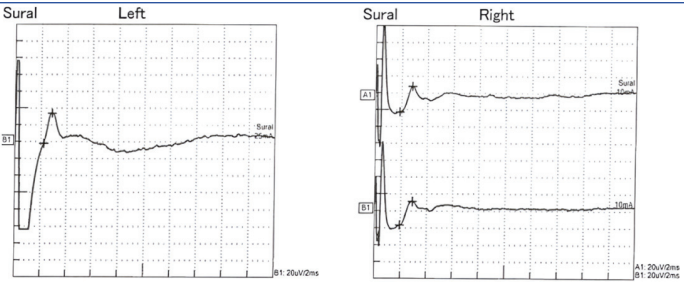
[Table/Fig-10a]: Motor nerve conduction of: Right and left median nerve- Decreased CAMP amplitude (blue arrow), normal latency and conduction velocity. Right and left ulnar nerve- Decreased CAMP amplitude (red arrow), normal latency and conduction velocity. Right and left peroneal nerve - Decreased CAMP amplitude (yellow arrow), normal latency and conduction velocity.



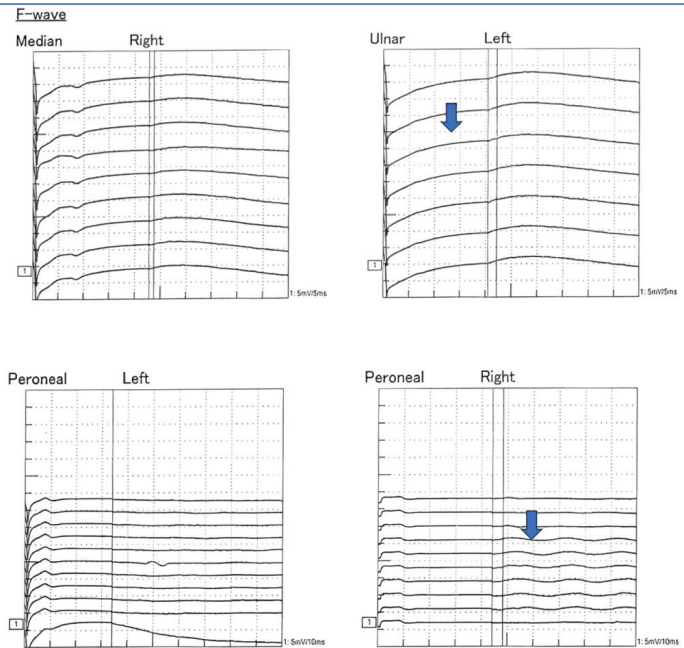
[Table/Fig-10b]: Motor Nerve Conduction of Right and Left Tibial Nerve- Decreased CAMP amplitude (blue arrow), normal latency and conduction velocity.



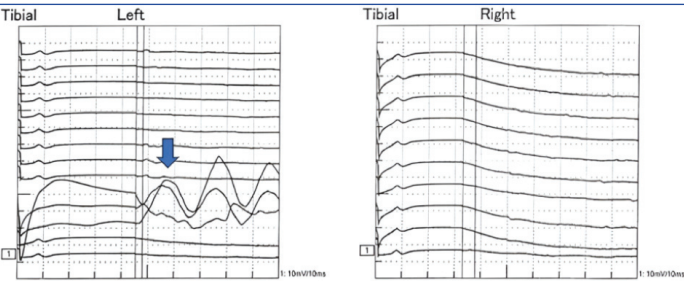
[Table/Fig-11a]: Sensory Nerve Conduction of: Right and Left Median - Normal SNAP amplitude, normal distal latency and conduction velocity. Right and Left Ulnar- Normal SNAP amplitude, normal distal latency and conduction velocity.



[Table/Fig-11b]: Sensory Nerve Conduction of Right and Left Sural- Normal SNAP amplitude, normal distal latency and conduction velocity.



[Table/Fig-12a]: Showing Absent F-waves in bilateral median, bilateral ulnar and left peroneal nerves with Impersistent F waves in right peroneal nerve (marked in blue arrow).



[Table/Fig-12b]: Showing Absent F-waves in right tibial nerve with impersistent F-wave in left tibial nerve (marked in blue arrow).

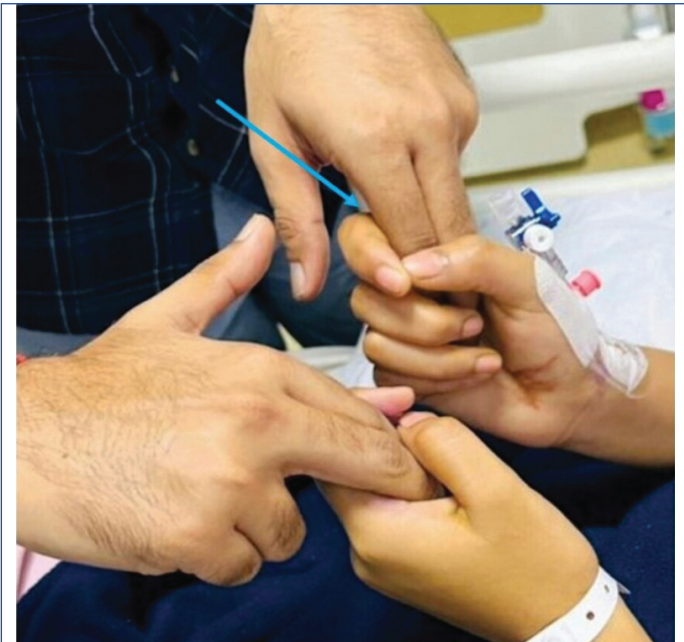Investigation	Value	Reference range
Haemoglobin (g/dL)	9.3	11.5-15.0
Total leukocyte count (/µL)	7,700	4000-10,000
Platelet count (/µL)	3,02,000	150000-410000
Mean corpuscular volume (fL)	76	78-98
Serum bilirubin (mg/dL)	0.29	0.2-1.20
Conjugated bilirubin (mg/dL)	0.15	Upto 0.5
Unconjugated bilirubin (mg/dL)	0.14	0.1-1.0
AST (U/L)	28	8-48
ALT (U/L)	27	7-55
Alkaline phosphatase (U/L)	60	40-130
Protein (Total) (g/dL)	7.40	6.4-8.3
Serum albumin (g/dL)	3.80	3.5-5.2
Serum magnesium (mg/dL)	2.0	1.8-2.40
Serum phosphorus (mg/dL)	4.10	2.6-4.7
Serum sodium (mmol/L)	138.0	136-145

Serum potassium (mmol/L)	4.10	3.50-5.10
Serum chloride (mmol/L)	104	98-107
Urea (mg/dL)	23	17-49
Serum creatinine (mg/dL)	0.50	0.6-1.35
Serum calcium (mg/dL)	9.10	8.60-10.2

[Table/Fig-13]: Post-treatment laboratory investigations.
fL: Femtoliters; microL: Microliter; g/dL: Grams per deciliter; mg/dL: Milligrams per deciliter; U/L: Units per liter; mmol/L: Millimoles per litre

Joints	Day 1 (right)	Day1 (left)	Day 10 (right)	Day 10 (left)	Day 21 (right) (on discharge)	Day 21 (left) (on discharge)
Shoulder:						
Abduction	4/5	4/5	3/5	3/5	4/5	4/5
Adduction	4/5	4/5	3/5	3/5	4/5	4/5
Flexion	3/5	3/5	2/5	2/5	4/5	4/5
Extension	3/5	3/5	2/5	2/5	4/5	4/5
Elbow:						
Flexion	2/5	2/5	3/5	3/5	4/5	4/5
Extension	2/5	2/5	3/5	3/5	4/5	4/5
Wrist:						
Dorsiflexion	3/5	3/5	2/5	2/5	3/5	3/5
Plantarflexion	3/5	3/5	2/5	2/5	3/5	3/5
Hip:						
Flexion	3/5	3/5	1/5	1/5	3/5	3/5
Extension	3/5	3/5	1/5	1/5	3/5	3/5
Abduction	2/5	2/5	1/5	1/5	3/5	3/5
Adduction	2/5	2/5	1/5	1/5	3/5	3/5
Knee:						
Flexion	4/5	4/5	2/5	2/5	3/5	3/5
Extension	4/5	4/5	2/5	2/5	3/5	3/5
Ankle:						
Dorsiflexion	3/5	3/5	1/5	1/5	3/5	3/5
Plantarflexion	4/5	4/5	3/5	3/5	4/5	4/5
Hand grip	Weak	Weak	Weak	Weak	Improved	Improved

[Table/Fig-14]: Progression and improvement in the weakness from day of admission to day of discharge.



[Table/Fig-15]: Improved hand grip (blue arrow) post Intravenous Immunoglobulin (IVIg).

The patient came to the Outpatient Department (OPD) for follow-up after six weeks of discharge. On examination, power in her upper

and lower limb muscles had improved. She was able to walk on her own and carry out her daily activities. A repeat obstetric scan revealed an intrauterine foetus of 25 weeks with no obvious anomaly. The patient was advised to continue with physiotherapy and to remain under the care of the obstetrics and gynecology department for further management.

DISCUSSION

The rare neurological condition known as GBS is characterised by an immune system attack on the peripheral nervous system [2]. Leg weakness and tingling are common early symptoms that may extend to other parts of the body. The severity can vary greatly, ranging from weakness to complete loss of muscle function [3]. This can cause numbness, paralysis, or muscle weakness [4].

With a case incidence of 1-2 per 1,000,000, GBS is an uncommon autoimmune disease that can occur during pregnancy [4]. The risk of GBS may increase slightly in the postpartum period or during the second or third trimester, as observed in this case [4]. GBS is sometimes preceded by illnesses such as gastrointestinal, respiratory, or viral infections. These infections are often caused by bacteria like *Campylobacter jejuni*, *Mycoplasma pneumoniae*, or *Haemophilus influenzae*, as well as viruses like Epstein-Barr virus or Varicella zoster virus [4]. Other triggers include surgery and, rarely, vaccination. Although the precise aetiology of GBS isn't always known, infections like respiratory or gastrointestinal infections are often the first to manifest before GBS [5]. Rarely, vaccinations or other triggers are also linked to cases [5].

Turtle J et al., presented a comprehensive analysis of an atypical instance of GBS that arose following the administration of a vaccine containing tetanus toxoid [6]. GBS causes abrupt muscle paralysis as a consequence of an autoimmune illness, usually occurring following infections [6]. The correlation between GBS with various immunisations, such as the influenza vaccine, is widely documented; however, there are less instances linking GBS with the Tetanus Toxoid vaccine [6]. The patient states that GBS developed following the administration of a tetanus toxoid vaccine booster, with no other apparent aetiology for GBS discovered [6].

Pregnancy-related GBS, though uncommon, is a serious condition that requires specialised care to ensure the wellbeing of both the mother and the foetus. GBS can occur at any point during pregnancy and needs to be carefully managed to protect the health of both the mother and the foetus [7]. While GBS can develop at any stage of pregnancy, it is a rare and dangerous illness that needs to be carefully managed to protect the growing foetus and the mother [7].

IVIg and plasmapheresis are the mainstay treatment protocol for GBS [5,8]. Supportive care also plays a crucial role in the prognosis of the disease. Recovery from the disease may be slow and some people may develop long-term complications; but early diagnosis and treatment have led to good outcomes in the patients.

Vaccine-associated GBS is characterised by the occurrence of GBS symptoms within a period of six weeks after getting a vaccine, as stated by the Vaccine Adverse Event Reporting System (VAERS) [9]. Vaccines frequently linked to GBS include the meningococcal vaccine, poliovirus vaccine, influenza vaccine, rabies vaccine and, exceptionally, the tetanus vaccine. The incidence of GBS following tetanus vaccination is highly unlikely. The exact mechanism by which the tetanus vaccine may potentially induce GBS is not completely understood. There is a hypothesis that suggests that in extremely rare instances, the immune response to the vaccine may interact with elements of the peripheral nerves, resulting in an autoimmune assault [2]. Molecular mimicry is a proposed mechanism in which the immune system mistakenly identifies a portion of the vaccination antigen as nerve tissue.

There have been persistent doubts regarding the actual correlation between GBS and vaccines or other events that occur around the same time as vaccination. The relationship between GBS and the

tetanus toxoid immunisation is not well understood. Several studies have indicated a possible association between GBS and vaccines that include tetanus toxoid [9]. While there have been some sporadic instances of GBS occurring after receiving the tetanus toxoid vaccine, there is currently no conclusive evidence establishing a direct connection between the immunisation and GBS [9]. Hence, additional investigation is imperative to gain a more comprehensive understanding of the correlation between GBS and DTP vaccinations. Since the initial report of demyelinating neuropathy resulting from tetanus vaccination in 1978, several individual cases of GBS have been documented following the administration of tetanus toxoid [9]. In 1978, the GBS case experienced the development of acute demyelinating polyneuropathy syndrome following the administration of tetanus toxoid injections [9]. Furthermore, there have been documented cases of Miller-Fisher Syndrome (MFS), which is a variant of GBS, occurring after receiving the DTP immunisation [9].

Kongbunkiat K et al., described four separate cases of GBS that occurred after receiving the diphtheria-tetanus (dT) vaccine during a diphtheria outbreak in Thailand [10]. The majority of the individuals who acquired GBS which became more common after their second dT immunisation, for individuals aged 60 years and up [10]. The patients complained of muscle weakness and loss of reflexes and some even suffered from facial paralysis. The authors investigated the possibility that the documented cases of GBS are caused by the development of an autoimmune process in response to vaccination. However, the chance of such an occurrence is quite low, estimated at 0.29 cases per 100,000 doses and in the event of epidemics, the advantages of providing the diphtheria-tetanus vaccination significantly outweigh the risks [10].

Another study conducted by Ammar H, described an unusual correlation between vaccines containing tetanus toxoid, specifically the Tdap (tetanus, diphtheria, pertussis) accephalus and GBS [11]. A relatively small number of GBS-tetanus vaccine correlations have been reported and even fewer suggest a cause-and-effect relationship in tetanus cases. Given that the patient in this case had symptoms of GBS a week after receiving the Tdap vaccine, the case report supports this relationship. According to the Advisory Committee on Immunisation Practices, tetanus toxoid vaccinations should be supported and used with caution, particularly for individuals who have had GBS within the six weeks since their last vaccination [11].

CONCLUSION(S)

Pregnancy-related GBS caused by tetanus immunisation is an extremely rare occurrence that needs to be diagnosed and treated effectively. When suspecting GBS, one should carefully consider the patient's history of immunisation. We don't discourage immunisation during pregnancy, as it has more advantages than disadvantages. Prompt diagnosis and therapy are essential for effectively managing GBS patients. IVIg and plasmapheresis have been the mainstays of treatment. Both are thought to be efficient and safe to use while pregnant. Most pregnant women with GBS have a positive prognosis if they receive the right care. In patients who have just had a vaccination, the clinician must be on the lookout for symptoms of GBS, particularly if they have neurological symptoms.

REFERENCES

- [1] Bates I. Reference ranges and normal values. Dacie and Lewis Practical Haematology. 2017;8:1-17.
- [2] Laman JD, Huizinga R, Boons GJ, Jacobs BC. Guillain-Barré syndrome: Expanding the concept of molecular mimicry. Trends Immunol. 2022;43(6):296-308. Doi: 10.1016/j.it.2022.02.003.
- [3] Leonhard SE, Mandarakas MR, Gondim FAA, Bateman K, Ferreira MLB, Cornblath DR, et al. Diagnosis and management of Guillain-Barré syndrome in ten steps. Nat Rev Neurol. 2019;15(11):671-83. Available from: <https://doi.org/10.1038/s41582-019-0250-9>.
- [4] Rupalakshmi V, Shetty S. Guillain-Barré syndrome in pregnancy and its association with maternal and perinatal outcome. Muller J Med Sci Res. 2019;10(2):58. Doi: 10.4103/mjmsr.mjmsr_32_19.

[5] van Doorn PA, Van den Bergh PYK, Hadden RDM, Avau B, Vankrunkelsven P, Attarian S, et al. European Academy of Neurology/Peripheral Nerve Society Guideline on diagnosis and treatment of Guillain-Barré syndrome. *Eur J Neurol*. 2023;30(12):3646-74. Doi: 10.1111/ene.16073.

[6] Tuttle J, Chen RT, Rantala H, Cherry JD, Rhodes PH, Hadler S. The risk of Guillain-Barré syndrome after tetanus-toxoid-containing vaccines in adults and children in the United States. *Am J Public Health*. 1997;87(12):2045-48. Available from: <https://doi.org/10.2105/ajph.87.12.2045>.

[7] Hledíková A, Hruban L, Jura R, Sas I, Hrdý O, Janku P. Guillain-Barré syndrome in pregnancy. *Ceska Gynekol*. 2021;86(3):189-93. Doi: 10.48095/cccg2021189.

[8] Diggikar PM, Pancholi T, Yammanuru B, Mundada M, Janani R. Exploring treatments for a rare Guillain-Barré variant: A case report of Miller-Fisher syndrome. *Cureus*. 2024;16(7):e65561. Doi: 10.7759/cureus.65561.

[9] Pan M, Sun T, Zhu W, Liu H, Dong H. Guillain Barré syndrome after combined diphtheria tetanus and acellular pertussis (DTaP) vaccine: A rare pediatric case report and review of literature. *Hum Vaccin Immunother*. 2023;19(2):2261199. Doi: 10.1080/21645515.2023.2261199.

[10] Kongbunkiat K, Kasemsap N, Tiangkao S, Sawanyawisuth K. Clinical manifestations and outcomes of Guillain-Barré syndrome after diphtheria and tetanus vaccine (dT) during a diphtheria outbreak in Thailand: A case series. *Neurol Asia*. 2014;19(2):137-55. Available from: <https://www.researchgate.net/publication/286411680>.

[11] Ammar H. Guillain-Barré syndrome after tetanus toxoid, reduced diphtheria toxoid and acellular pertussis vaccine: A case report. *J Med Case Reports*. 2011;5:502. Available from: <https://doi.org/10.1186/1752-1947-5-502>.

PARTICULARS OF CONTRIBUTORS:

1. Professor, Department of General Medicine, Dr. D. Y. Patil Medical College, Hospital and Research Centre, Pune, Maharashtra, India.
2. Junior Resident, Department of General Medicine, Dr. D. Y. Patil Medical College, Hospital and Research Centre, Pune, Maharashtra, India.
3. Junior Resident, Department of General Medicine, Dr. D. Y. Patil Medical College, Hospital and Research Centre, Pune, Maharashtra, India.
4. Assistant Professor, Department of General Medicine, Dr. D. Y. Patil Medical College, Hospital and Research Centre, Pune, Maharashtra, India.
5. Junior Resident, Department of General Medicine, Dr. D. Y. Patil Medical College, Hospital and Research Centre, Pune, Maharashtra, India.

NAME, ADDRESS, E-MAIL ID OF THE CORRESPONDING AUTHOR:

Dr. Prince Yadav,
PG Boys Hostel, C-55, Dr. D. Y. Patil Medical College and Hospital,
Pune-411018, Maharashtra, India.
E-mail: princeera22@gmail.com

PLAGIARISM CHECKING METHODS: [Jain H et al.]

- Plagiarism X-checker: Sep 20, 2024
- Manual Googling: Oct 23, 2024
- iTenticate Software: Nov 13, 2024 (5%)

ETYMOLOGY: Author Origin

EMENDATIONS: 7

AUTHOR DECLARATION:

- Financial or Other Competing Interests: None
- Was informed consent obtained from the subjects involved in the study? Yes
- For any images presented appropriate consent has been obtained from the subjects. Yes

Date of Submission: Sep 16, 2024

Date of Peer Review: Oct 16, 2024

Date of Acceptance: Nov 15, 2024

Date of Publishing: Jan 01, 2025